PREVENTIVE CARE JOURNAL

(Online ISSN: 3139-2644) Vol. 2 No. 1 **(November 2026)**

Birth-Related Cervical Spine Injuries in Newborns Risk Factors Clinical Manifestations, Diagnosis and Management

Barno Rabieva*

Keywords:

Neonatal birth trauma, Cervical spine injury, Neonatal spinal cord injury, Obstetric trauma, Neurological complications, Neonatal hypotonia.

A B S T R A C T

Background: *Birth-related injuries of the cervical spine and spinal cord are rare but potentially life-threatening complications of the neonatal period. These injuries may result in neurological impairment, respiratory dysfunction, motor deficits, and long-term developmental disabilities. The anatomical and biomechanical characteristics of the neonatal cervical spine, including ligamentous flexibility, immature vertebral structures, and relatively weak cervical musculature, contribute to its vulnerability to excessive mechanical forces during childbirth.*

Objective: *This review aims to examine the etiological factors, pathophysiological mechanisms, clinical manifestations, diagnostic approaches, and contemporary management strategies for birth-related cervical spine injuries in newborns, with particular emphasis on early recognition and prevention of neurological complications.*

Methods: *A narrative review approach was adopted to synthesize published clinical studies, case reports, and relevant recommendations concerning neonatal cervical spine trauma. Particular attention was given to obstetric risk factors, mechanisms of spinal cord injury, neurological assessment, and the diagnostic utility of magnetic resonance imaging (MRI), ultrasonography, and other imaging modalities.*

Results: *The reviewed literature identifies difficult or complicated delivery, breech presentation, shoulder dystocia, and excessive traction, rotation, or hyperextension of the fetal neck as potential contributing factors. Clinical manifestations vary according to the anatomical location and severity of injury and may include generalized hypotonia, reduced spontaneous movements, limb weakness, abnormal reflexes, respiratory insufficiency, and, in severe cases, paralysis. Magnetic resonance imaging plays a central role in detecting spinal cord abnormalities and associated soft-tissue injuries. Timely neurological assessment, appropriate stabilization, multidisciplinary management, and individualized follow-up are essential components of clinical care.*

Conclusion: *Birth-related cervical spine injuries represent an important diagnostic challenge in neonatal medicine because their initial manifestations may be subtle or overlap with other neonatal neurological disorders. Early identification of risk factors, careful neurological examination, appropriate neuroimaging, and coordinated management involving neonatologists, pediatric neurologists, radiologists, and neurosurgeons are important for improving diagnostic accuracy and guiding treatment. Further prospective research is needed to establish standardized diagnostic pathways, evaluate long-term neurological outcomes, and strengthen evidence-based prevention strategies.*

1. INTRODUCTION

Birth-related trauma remains an important concern in neonatal medicine because of its potential association with neurological impairment, respiratory complications, and long-term functional disabilities. Although advances in obstetric management, prenatal monitoring, and neonatal intensive care have improved perinatal outcomes, traumatic injuries involving the cervical spine and spinal cord continue to present substantial diagnostic and therapeutic challenges. These injuries are relatively uncommon compared with other forms of neonatal birth trauma, yet their consequences may be severe,

* Assistant Lecturer, Department of Faculty Pediatrics and Neonatology
Andijan State Medical Institute, Uzbekistan
Email: r.bobomurod.rp@gmail.com

particularly when the upper cervical spinal cord is involved (Gumayan et al., 2025).

The neonatal cervical spine possesses distinctive anatomical and biomechanical characteristics that influence its susceptibility to injury. In newborns, the vertebral column is characterized by incomplete ossification, relatively flexible ligamentous structures, immature paraspinal musculature, and a disproportionately large head relative to body size. These developmental characteristics may increase vulnerability to excessive traction, rotation, flexion, or hyperextension forces during complicated childbirth. Importantly, the elasticity of the neonatal vertebral column may exceed that of the spinal cord, allowing neurological damage to occur without obvious vertebral fracture or dislocation. Consequently, clinically significant spinal cord injuries may remain undetected when diagnostic assessment relies predominantly on conventional skeletal imaging.

The mechanisms underlying birth-related cervical spine injuries are multifactorial and may involve both mechanical and nonmechanical processes. Obstetric circumstances traditionally associated with neonatal spinal trauma include breech presentation, difficult fetal extraction, shoulder dystocia, and instrument-assisted delivery. Excessive longitudinal traction, rotation, or hyperextension of the fetal neck may contribute to ligamentous disruption, vertebral instability, spinal cord compression, or direct neurological injury. However, the presence of these obstetric factors does not necessarily establish a causal relationship, and neonatal spinal cord abnormalities may also arise from ischemic, vascular, congenital, or other pathological conditions (Gumayan et al., 2025)

2. LITERATURE REVIEW

Birth-related injuries of the cervical spine and spinal cord constitute a rare but clinically significant category of neonatal trauma. Unlike more frequently recognized birth injuries, including clavicular fractures, cephalohematomas, and brachial plexus injuries, cervical spinal cord lesions may remain undetected during the immediate postnatal period because of their variable clinical presentation and overlap with other neonatal neurological disorders.

Gumayan et al. (2025), in their review published in *NeoReviews*, emphasized that neonatal spinal cord injury represents a heterogeneous clinical condition with multiple potential etiologies, including mechanical trauma, prenatal or perinatal ischemia, iatrogenic injury, congenital spinal abnormalities, and neoplastic processes. The authors presented four clinical cases illustrating the diagnostic complexity of neonatal spinal cord injury and the difficulties involved in establishing a definitive mechanism of injury. Their findings challenge the assumption that neonatal spinal cord abnormalities are necessarily attributable to mechanical trauma during delivery.

The epidemiological assessment of birth-related cervical spine injuries remains problematic. Palchik et al. (2024) reported that the true incidence of neonatal birth-related spinal cord injury is uncertain, partly because of its rarity, inconsistent diagnostic classifications, and difficulties distinguishing traumatic from nontraumatic causes. The absence of standardized population-based surveillance further limits the comparability of published findings.

Earlier multicenter observations provide valuable clinical evidence but cannot establish contemporary population-level incidence. In a study involving nine children with birth-related spinal injuries, cervical spinal involvement was identified in six cases. Although clinically important, these findings represent a selected case series rather than a representative neonatal population.

Consequently, currently available evidence supports the clinical importance of cervical spinal injuries but does not justify precise estimates of their incidence or prevalence across different healthcare systems.

The neonatal cervical spine differs considerably from the mature spinal column in its anatomical composition, mechanical properties, and physiological stability. The relatively large neonatal head, incompletely ossified vertebral structures, flexible ligaments, and immature supporting musculature create a distinctive biomechanical environment.

These developmental characteristics influence the distribution of forces acting on the cervical spine during childbirth. Excessive traction, rotation, or hyperextension may cause displacement or stretching of spinal structures, potentially resulting in ligamentous disruption, spinal cord injury, hemorrhage, or vertebral instability.

Palchik et al. (2024) described longitudinal and lateral traction, as well as excessive rotational forces, as important mechanisms implicated in neonatal spinal cord injury. The authors also emphasized the need for caution when interpreting mechanical mechanisms because spinal injuries have occasionally been reported following deliveries without obvious traumatic complications.

The relatively greater elasticity of the neonatal vertebral column compared with the spinal cord may permit neurological injury even when conventional radiographic evidence of fracture or dislocation is absent. This anatomical characteristic is especially relevant when evaluating newborns with unexplained neurological abnormalities following complicated delivery.

3. RESULTS AND ANALYSIS

This narrative review identifies several recurring themes in the literature on birth-related cervical spine and spinal cord injuries in newborns: diagnostic uncertainty, the importance of anatomical assessment, individualized management, and limited evidence for specific therapeutic interventions. These findings represent a qualitative synthesis of published reports, not original patient data or pooled estimates.

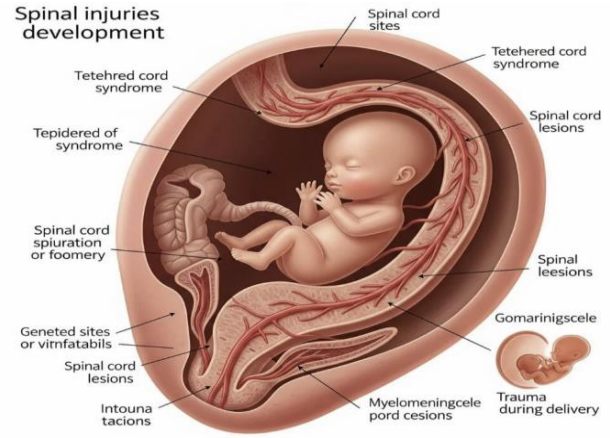

Figure-1 Spinal Cord Injuries Birth: Causes, Impact, and Legal Action

Birth-related cervical spine injury is damage to a newborn's neck vertebrae, supporting ligaments, and/or cervical spinal cord caused by mechanical forces during childbirth. Its effects depend on the structures involved and the severity of injury and may include impaired movement, muscle weakness, and respiratory dysfunction**.**

Diagnostic Recognition and Etiological Uncertainty

A recurring finding is the difficulty of recognizing neonatal spinal cord injury from the initial clinical presentation. Hypotonia, reduced spontaneous movements, and respiratory dysfunction may overlap with manifestations of hypoxic–ischemic encephalopathy. A published case in which an upper spinal cord lesion was identified after an initial diagnosis of HIE illustrates this diagnostic problem. Persistent respiratory and motor abnormalities may therefore warrant further investigation when the initial diagnosis does not adequately explain the clinical course.

The literature also distinguishes recognition of a spinal lesion from identification of its cause. Mechanical trauma is one possible explanation, but ischemic, congenital, and iatrogenic mechanisms must also be considered. Consequently, a difficult delivery followed by neurological impairment does not independently establish traumatic causation. A stronger interpretation requires consistency between the perinatal history, examination findings, and anatomical distribution of injury.

Contribution of Imaging to Clinical Interpretation

MRI emerges as an important diagnostic tool because it provides information about spinal cord pathology that may be inadequately characterized by clinical examination or conventional radiography. In the four cases reported by Mills et al. (2001), early MRI demonstrated injury extent and severity and informed management. However, this evidence supports clinical usefulness rather than a numerical estimate of diagnostic accuracy.

The reviewed evidence further indicates that spinal cord damage and vertebral or ligamentous instability should be assessed separately. Reports involving cervical fractures and ligamentous abnormalities demonstrate how different imaging modalities can answer complementary anatomical questions. The analytical implication is that neurological impairment alone does not define mechanical stability, while skeletal findings alone may not fully explain neurological dysfunction.

Management Evidence and Treatment Interpretation

Published management approaches vary according to the injury pattern. A three-neonate case series described custom-fabricated external orthoses for cervical injuries associated with suspected instability. These observations provide practical examples of individualized stabilization, but the absence of a comparison group prevents conclusions about relative effectiveness.

Evidence for surgery is similarly limited to selected clinical circumstances. Successful repair and subsequent recovery have been reported in an infant with severe birth-related cervical fracture-dislocation. This finding demonstrates that surgical intervention can be feasible in a particular structural injury; it does not establish surgery as the preferred approach for neonatal spinal cord injury generally.

Neuroprotective interventions require especially cautious interpretation. A report of whole-body cooling combined with erythropoietin described an unsuccessful outcome. A single case cannot determine efficacy, identify treatment-responsive subgroups, or separate treatment effects from injury severity. The evidence examined therefore does not establish these interventions as effective treatments for isolated neonatal spinal cord injury.

Outcome Variability and Strength of Conclusions

Published cases illustrate both substantial recovery and severe adverse outcomes. This variation limits prognostic generalization and reinforces the need to interpret individual outcomes within their clinical and anatomical context. Neither a favourable surgical report nor an unsuccessful neuroprotective intervention provides a reliable estimate of the expected outcome for other newborns.

The principal methodological limitation of this synthesis is the predominance of case-based evidence. Case reports can reveal unusual presentations and potential management strategies, but they cannot establish incidence, independent risk factors, or comparative treatment effectiveness. Publication bias is also a plausible concern: unusually severe injuries and exceptional recoveries may be more likely to appear in the literature than less distinctive cases.

Overall, the evidence supports careful diagnostic assessment and management tailored to the demonstrated injury. It remains insufficient for precise outcome prediction or identification of a universally superior treatment strategy. These conclusions should be regarded as a narrative interpretation of limited clinical evidence rather than findings from a systematic review or meta-analysis.

4. CONCLUSION

Birth-related cervical spine and spinal cord injuries in newborns present substantial diagnostic and management challenges. Their clinical manifestations may overlap with other neonatal neurological conditions, particularly hypoxic–ischemic encephalopathy. Persistent or otherwise unexplained motor impairment and respiratory dysfunction should therefore raise consideration of spinal pathology. MRI is important for characterizing suspected spinal cord injury, while assessment of associated vertebral and ligamentous abnormalities helps guide management.

A central conclusion of this review is that a spinal lesion identified after birth should not automatically be attributed to mechanical trauma during delivery. Clinical interpretation requires consideration of alternative etiologies and integration of the perinatal history, neurological findings, and imaging evidence. Management should be individualized, with multidisciplinary attention to supportive care, structural stability, rehabilitation, and longitudinal follow-up.

The available literature remains dominated by case reports and small case series, limiting conclusions about incidence, independent risk factors, treatment effectiveness, and prognosis. Multicentre studies using standardized diagnostic definitions and functional outcome measures are needed to strengthen the evidence base. Until such evidence becomes available, reported treatment successes should be interpreted cautiously and distinguished from established therapeutic recommendations.

References:

Arnaez, J., Miranda, M., Riñones, E., & García-Alix, A. (2019). Whole-body cooling and erythropoietin in neonatal cervical spine injury. *Therapeutic Hypothermia and Temperature Management, 9*(2), 159–162. https://doi.org/10.1089/ther.2018.0042.

Brand, M. C. (2006). Part 1: Recognizing neonatal spinal cord injury. *Advances in Neonatal Care, 6*(1), 15–24. https://doi.org/10.1016/j.adnc.2005.11.001.

Goetz, E. (2010). Neonatal spinal cord injury after an uncomplicated vaginal delivery. *Pediatric Neurology, 42*(1), 69–71. https://doi.org/10.1016/j.pediatrneurol.2009.08.006.

Gumayan, R. L. F., Zarei, S., Ortiz, M., Spagnolo, K., & Christoffel, K. (2025). Neonatal spinal cord injury. *NeoReviews, 26*(11), e730–e742. https://doi.org/10.1542/neo.26-11-067.

Karthikeyan, V., Breitbart, S. C., Malhotra, A. K., Fung, A., Short, E., Schmitz, A., Lebel, D. E., & Ibrahim, G. M. (2023). Management of perinatal cervical spine injury using custom-fabricated external orthoses: Design considerations, narrative literature review, and experience from the Hospital for Sick Children. Illustrative cases. *Journal of Neurosurgery: Case Lessons, 5*(10), Article CASE22455. https://doi.org/10.3171/CASE22455.

Lee, C.-C., Chou, I.-J., Chang, Y.-J., & Chiang, M.-C. (2020). Unusual presentations of birth related cervical spinal cord injury. *Frontiers in Pediatrics, 8,* Article 514. https://doi.org/10.3389/fped.2020.00514.

MacKinnon, J. A., Perlman, M., Kirpalani, H., Rehan, V., Sauve, R., & Kovacs, L. (1993). Spinal cord injury at birth: Diagnostic and prognostic data in twenty-two patients. *The Journal of Pediatrics, 122*(3), 431–437. https://doi.org/10.1016/S0022-3476(05)83437-7.

Menticoglou, S. M., Perlman, M., & Manning, F. A. (1995). High cervical spinal cord injury in neonates delivered with forceps: Report of 15 cases. *Obstetrics & Gynecology, 86*(4, Part 1), 589–594. https://doi.org/10.1016/0029-7844(95)00213-B

Mills, J. F., Dargaville, P. A., Coleman, L. T., Rosenfeld, J. V., & Ekert, P. G. (2001). Upper cervical spinal cord injury in neonates: The use of magnetic resonance imaging. *The Journal of Pediatrics, 138*(1), 105–108. https://doi.org/10.1067/mpd.2001.109195.

Morgan, C., & Newell, S. J. (2001). Cervical spinal cord injury following cephalic presentation and delivery by Caesarean section. *Developmental Medicine & Child Neurology, 43*(4), 274–276. https://doi.org/10.1017/S0012162201000512. cambridge.org

Palchik, A. B., Ivanov, D. O., Fomina, M. Y., Ponyatishin, A. E., & Minin, A. V. (2024). Povrezhdenie pozvonochnika i spinnogo mozga pri rodovoi travme (Proekt klinicheskikh rekomendatsii) [Birth

spine and spinal cord injury (Draft of the clinical recommendations)]. *Pediatrician (St. Petersburg), 15*(5), 111–125. https://doi.org/10.17816/PED155111-125.

Saleh, S., Swanson, K. I., & Bragg, T. (2018). Successful surgical repair and recovery in a 2-week-old infant after birth-related cervical fracture dislocation. *Journal of Neurosurgery: Pediatrics, 21*(1), 16–20. https://doi.org/10.3171/2017.7.PEDS17105.

Ul Haq, I., & Gururaj, A. K. (2012). Remarkable recovery in an infant presenting with extensive perinatal cervical cord injury. *BMJ Case Reports, 2012*, Article bcr2012007533. https://doi.org/10.1136/bcr-2012-007533.

Rabiev, B. B. (2026). Children's health in migrant families: Gender and care dynamics. Central Asian Journal of Medical and Natural Science, 7(2), 184–189. https://doi.org/10.51699/cajmns.v7i2.3136

Vialle, R., Piétin-Vialle, C., Ilharreborde, B., Dauger, S., Vinchon, M., & Glorion, C. (2007). Spinal cord injuries at birth: A multicenter review of nine cases. *The Journal of Maternal-Fetal & Neonatal Medicine, 20*(6), 435–440. https://doi.org/10.1080/14767050701288325.

Yokoi, K., Kobayashi, S., Muramatsu, K., Suzuki, S., & Gotou, H. (2017). The question of whether or not to perform therapeutic hypothermia: A case of neonatal spinal cord injury. *Journal of Neonatal-Perinatal Medicine, 10*(2), 195–198. https://doi.org/10.3233/NPM-171695.

Rabiev, B. B. (2026). *Women's migration and childhood illness social determinants of health*. *Journal of Family Medicine and Health Care, 12*(2), 27–32. https://doi.org/10.11648/j.jfmhc.20261202.11